

OMC Journal Club

Dr Dujon Fuzzard

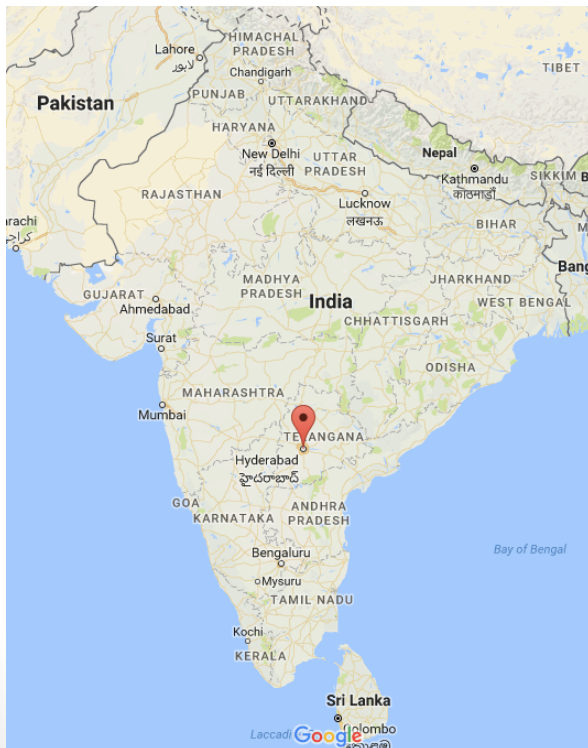Eye Registrar

October 2017

Augmented superior rectus transposition with medial rectus recession in patients with abducens nerve palsy

Preeti Patil-Chhablani, DNB,^a Krishnapriya Kothamasu, VR, DO,^a Ramesh Kekunnaya, FRCS,^a Virender Sachdeva, MS,^b and Vivek Warkad, MS^c

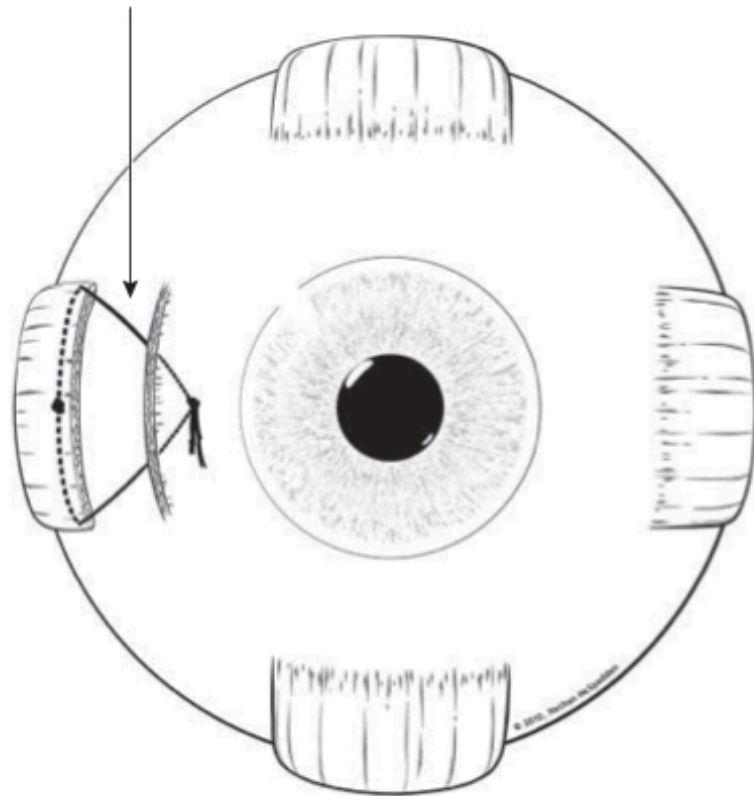
Journal of AAPOS Volume 20 Number 6 / December 2016



Augmented SRT + MRRc

A

MRRc with adjustable suture



B

SRT along spiral of Tillaux

Augmentation suture
8-12 mm posterior to insertion

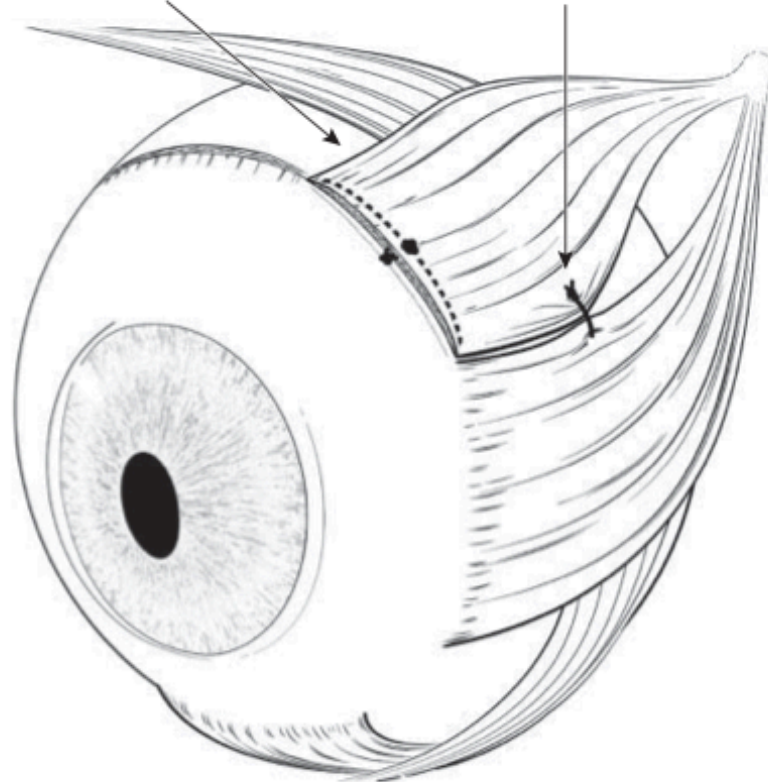


Image Source: Mehendale RA et al. Superior rectus transposition and medial rectus recession for Duane syndrome and sixth nerve palsy. *Arch Ophthalmol.* 2012;130(2):195-201.

Method

- Retrospective review
 - Jan 2012 to Dec 2014
- Exclusions reported
 - Previous surgery
 - Previous botox injections
- Surgery planned after documenting stability or at least 6 months post-trauma
- Pre-op forced duction testing in all patients
- SR hooked and secured with double armed 6-0 polygalactin 910 suture
- Foster suture: 5-0 polyester Dacron suture 8mm behind the insertion of LR
- 4 surgeons performed all procedures
- Planning based on a treatment effect of 15 prism diopter correction from SRT
- Success – horizontal deviation $<10^{\Delta}$
- Failure – residual ET $>20^{\Delta}$
- Abduction graded from 0 to -8 (0 no limitation, -4 unable to cross midline, -8 fixed extreme adducted position)

Table 1. Approximate guide for amount of medial rectus recession, in combination with superior rectus transposition

Esotropia in primary position, PD	Amount of MR recession, mm
30	4
40	5
50	5.5
60	6
70	6.5

MR, medial rectus muscle; *PD*, prism diopter.

Results

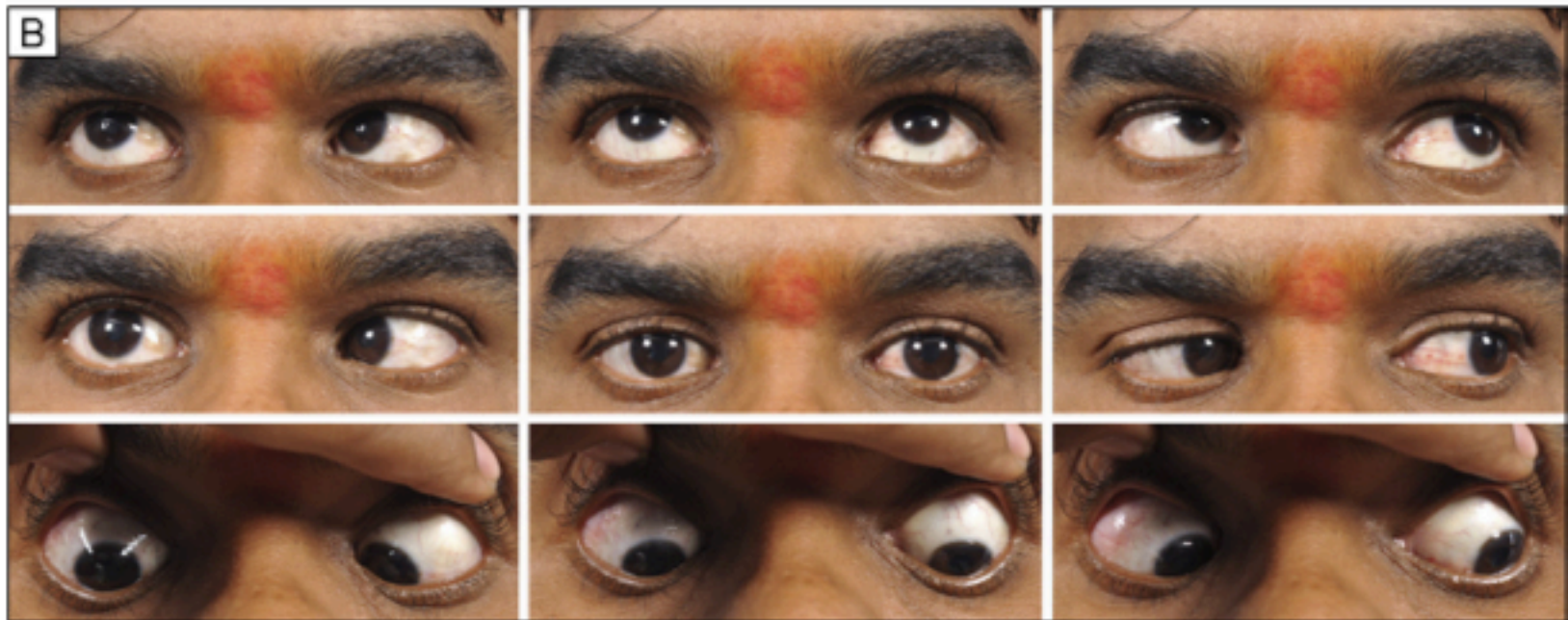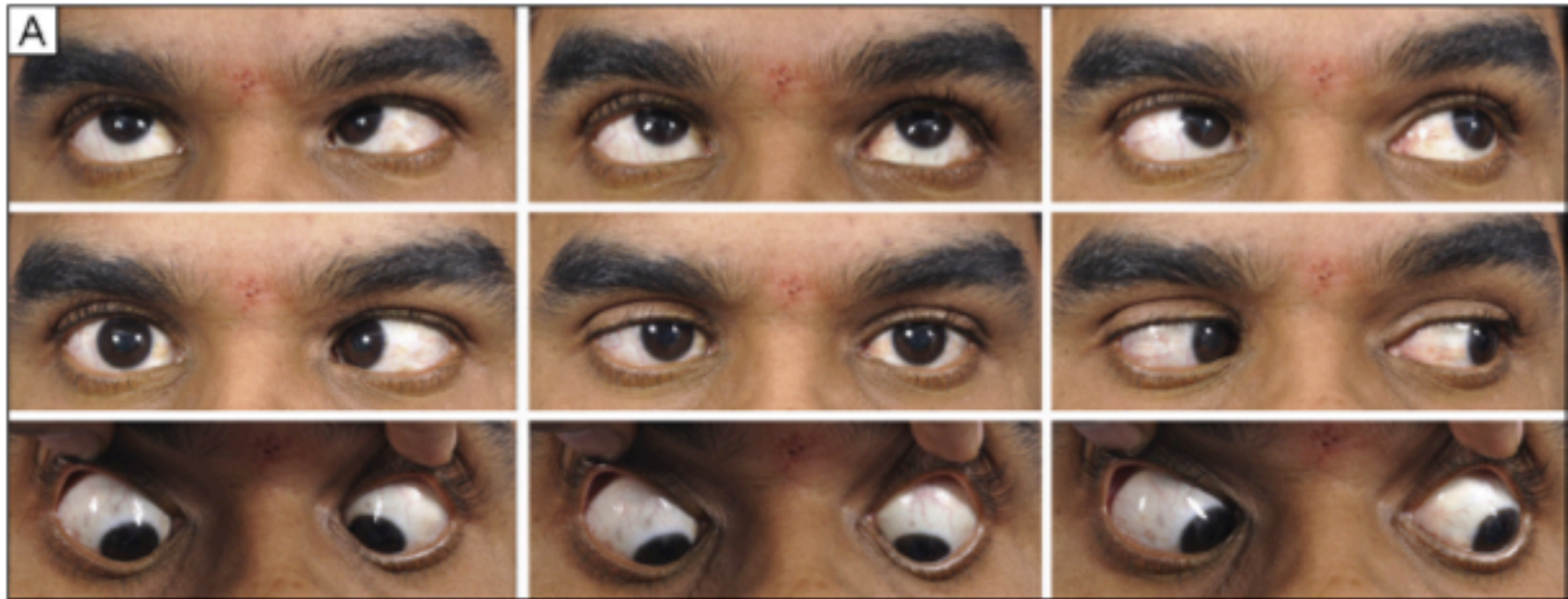- 17 subjects
 - 4 subjects excluded
 - 3 children <10yo and 1 adult with near-complete recovery of abduction
 - 13 subjects included for analysis
- Average MRRc performed 5.7mm (range 4.5-6.5mm)
- Mean post-op follow-up 5.2 months (range 1.5-12 months)
- 9/13 had deviation <10^Δ
- Tight MR on forced duction test in 6 eyes
- Head turn
 - Mean pre-op 21.6 degrees (range 10-30)
 - Mean post-op 7.2 degrees (range 0-15)

Results

Table 2. Characteristics of patients undergoing superior rectus transposition with medial rectus recession

Patient	Age, years	Sex	Eye affected	Etiology	Deviation, PD		Abduction		Complications/ additional treatment
					Before surgery	After surgery	Before surgery	After surgery	
1	36	M	R	Trauma	30	6	-4	-4	Nil
2	32	M	R	Congenital	65	0	-5	-2	Nil
3	21	M	L	Trauma	30	4	-5	-3	Nil
4	39	M	R	Trauma	30	0	-6	-3	Nil
5	63	M	R	CP angle tumor	50	10	-6	-3	Nil
6	60	M	R	Trauma	110	20	-5	-2	Nil
			L				-3	-2	Nil
7	45	M	R	Trauma	45	0	-5	-4	Transient postoperative HoT
8	65	F	R	Trauma	80	5	-6	-4	
9	41	F	L	Trauma	35	6	-4	-3	Nil
10	36	M	R	Trauma	85	15	-5	-4	Nil
			L				-5	-3	Nil
11	45	M	R	Trauma	40	0	-5	-3	Nil
12	43	M	R	Ischemic	60	12	-5	-3	Intorsion
13	38	F	R	Trauma	50	25	-5	-4	Comfortable with small head turn

HoT, hypotropia; IR, inferior rectus muscle; LR, lateral rectus muscle; MR, medial rectus muscle; PD, prism diopter.



Discussion

Table 3. Comparison of current study with previous studies describing SRT and VRT for abducens nerve palsy

Study	No. with abducens nerve palsy	Type of surgery	Mean esotropia, PD		Mean abduction deficit		Induced vertical deviation
			Before surgery	After surgery	Before surgery	After surgery	
Mehendale et al ⁵	7	Augmented SRT with adjustable MRc	47.42	8.71	—	—	2 (HoT)
Velez et al ⁸	7	Augmented SRT with adjustable MRc	53.5	16.8	-4.8	-3	1 (HoT) 5 (HT)
Britt et al ¹¹	5	Augmented partial VRT	45.2	-5	-4.45	-2.87	0
Yazdian et al ¹⁰	24	Augmented VRT	44.7	12.5	-4.22	-2.29	—
Simons et al ⁹	7	Augmented VRT	36.7	7.1	-3.78	-2.64	—
Present study	17	Augmented SRT with MRc with fixed sutures	56.88	10.82	-4.85	-2.85	1 (HoT)

HoT, hypotropia; *MRc*, *HT*, hypertropia; medial rectus recession; *PD*, prism diopter; *SRT*, superior rectus transposition; *VRT*, vertical rectus transposition.

OMC Journal Club

Dr Dujon Fuzzard

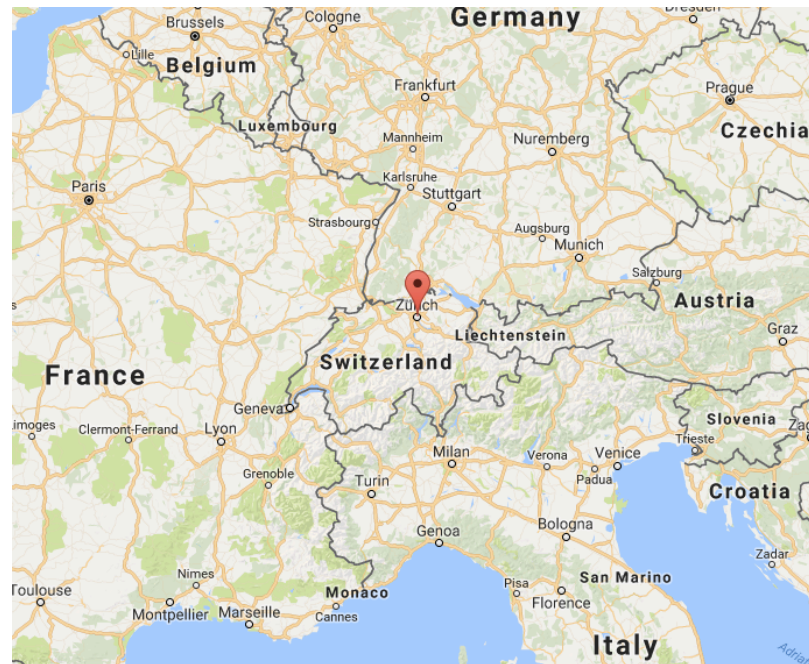Eye Registrar

October 2017

Long-term results of vertical rectus muscle transposition and botulinum toxin for sixth nerve palsy

Hana Leiba, MD,^{a,b,c} Gabriela M. Wirth, MD,^c Christoph Amstutz, MD, PhD,^c and Klara Landau, MD^c

Journal of AAPOS *Volume 14 Number 6 / December 2010*



VRT with MR botox

5 units of botox to MR
under direct visualisation

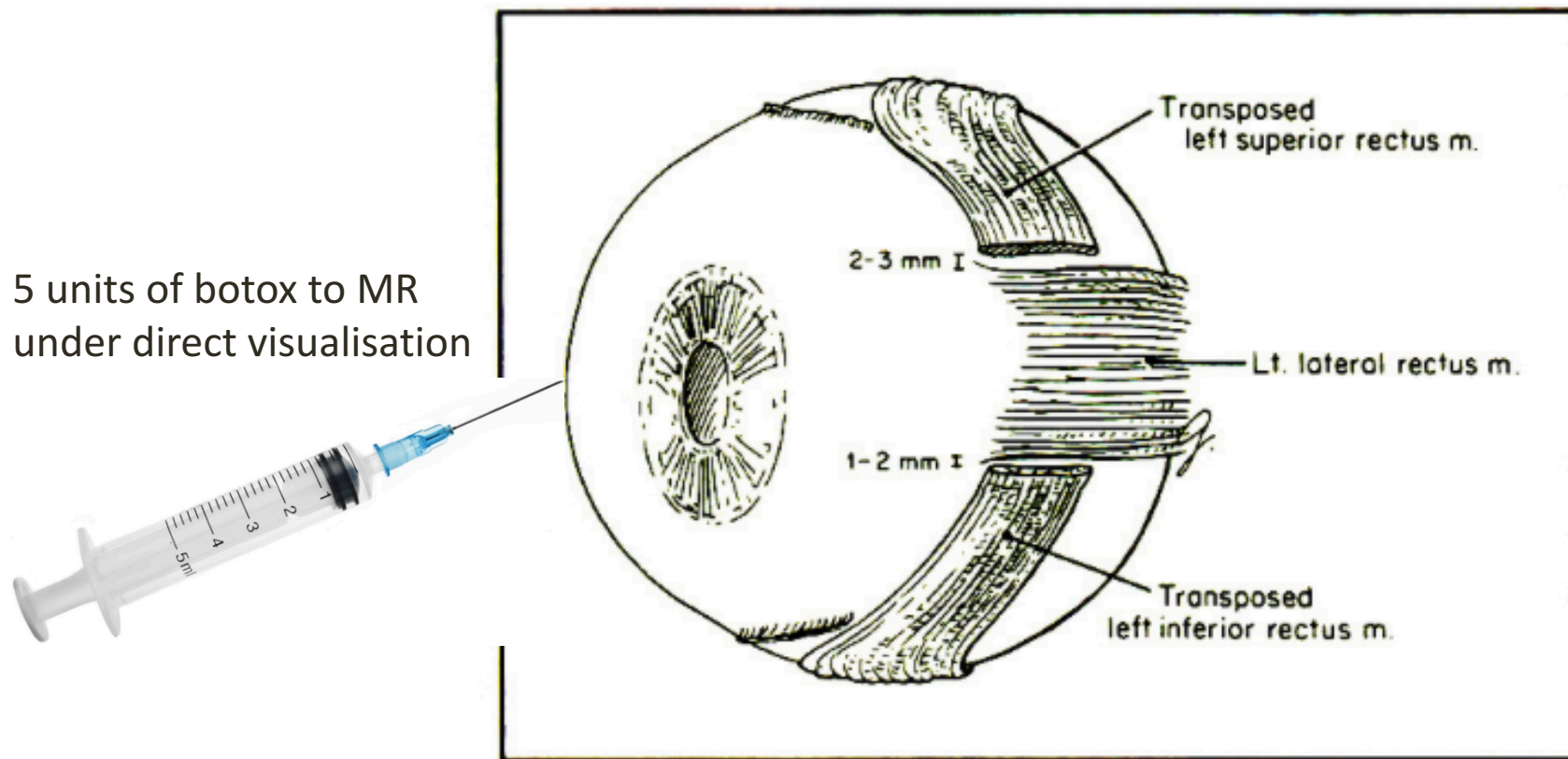


FIGURE 1: Schematic drawing depicting transposition of the left superior rectus and left inferior rectus to the left lateral rectus muscle.

Methods

- Retrospective review
- March 1992 to July 2003
- Abduction severely reduced in all cases
- All patients had pre-operative diplopia in primary position
- Palsy present for >1 year pre-op
- Follow-up 3 months and 1 year for all
- Additional data reported from final follow-up visit
- Abduction graded from 0 to -8 (0 no limitation, -4 unable to cross midline, -8 fixed extreme adducted position)

Results

- 22 patients
 - 19 adults, 15 males
- Mean age at surgery 41.7 ± 19.1 years (range 4.5-69)
- Cause of 6th nerve palsy
 - 10 head trauma
 - 11 tumour
 - 1 idiopathic
- 4/22 had Previous recession/resection elsewhere prior.
- Duration of follow-up: mean 44.2 ± 37.4 months (range 12-123)

Results

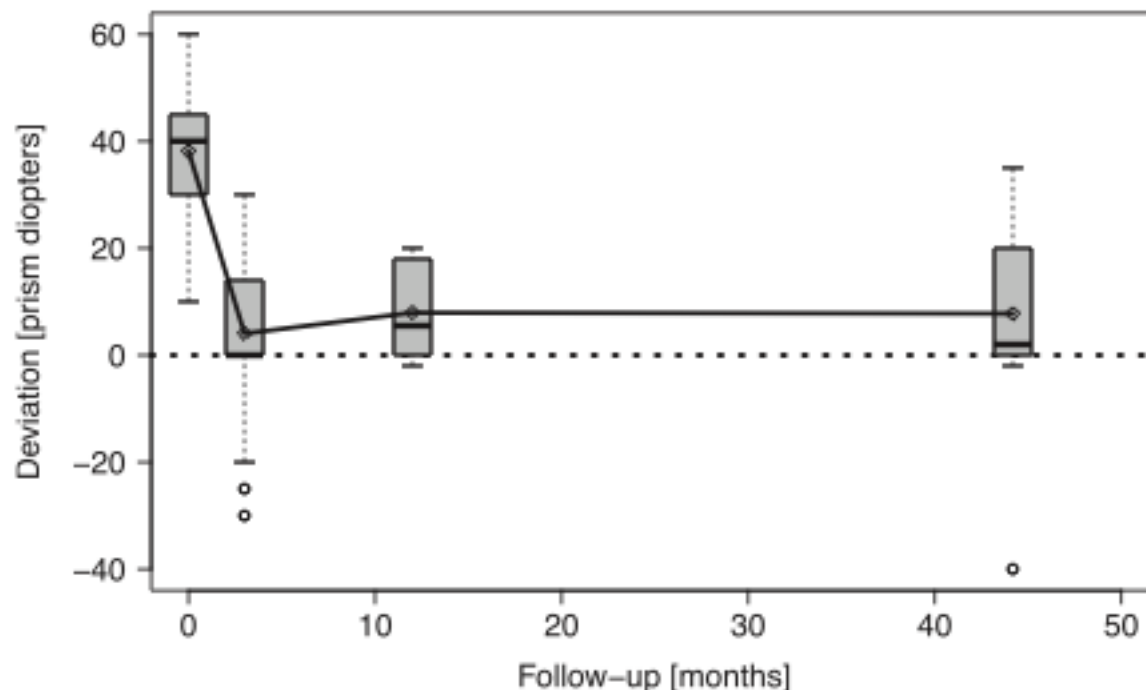


FIG 1. Angle of distance deviation over time. The mean angle of deviation, indicated by diamonds, was $38.1^{\Delta} \pm 11.6^{\Delta}$ before surgery, and $4.4^{\Delta} \pm 16.1^{\Delta}$ at 3 months, $9.4^{\Delta} \pm 8.1^{\Delta}$ at 12 months, and $7.8^{\Delta} \pm 15.8^{\Delta}$ at last follow-up after surgery. Box-and-whiskers plot: boxes indicate median and quartiles of angle of deviation. Whiskers extend to the largest and smallest data points that are no more than 1.5 times the interquartile range from the box, with outliers indicated by circles.

Results

- At final visit:
 - Average mean reduction of esotropic deviation $30^{\Delta} \pm 15.8^{\Delta}$ (range 6-75 $^{\Delta}$)
 - 13/22 within 10 $^{\Delta}$ of alignment
 - One patient developed a large sensory XT due to late visual loss in the non-paretic fellow-eye
- Induced vertical deviation
 - Present in 7/22 patients (32%)
 - 1 case of 4th nerve palsy (due to cavernous sinus meningioma that also caused the 6th)
 - 1/7 treated with prisms
 - 1/7 3.5mm IRRc in fellow eye
 - 5/7 opted not to have further treatment
- Sensory outcome
 - 16/22 no diplopia in primary position at final exam
 - 5/22 no diplopia due to suppression
- No cases of anterior segment ischaemia

Discussion

- No significant change in degree of deviation between 12 month visit and final visit, suggests VRT and MR botox is a reliable and long lasting treatment for complete chronic 6th nerve palsy.
- Risk of undesired vertical deviation likely due to vertical muscle transposition rather than botox injection